

## A woman with acquired, diffuse, lanugo-like hair growth

A 79-year-old woman presented with a 3-month history of rapid growth of multiple long, thin, non-pigmented hairs, distributed diffusely over the entire body, preferentially on the face and trunk (Figure, A). After extensive investigations, two neoplasms were detected — a breast mucinous carcinoma and a metastatic endometrial carcinoma (Figure, B) — establishing the diagnosis of paraneoplastic hypertrichosis lanuginosa acquisita.

Acquired hypertrichosis is strongly associated with underlying neoplasm (mainly lung and colorectal cancer).<sup>1,2</sup> Therefore,

detailed and extensive investigations are mandatory to detect the associated malignancy and to allow early and specific therapy.

**Marta Ferran**, Dermatologist

**Montserrat Gilaberte**, Dermatologist

**Josep E Herrero-Gonzalez**, Dermatologist

**Lara Pijuan**, Pathologist

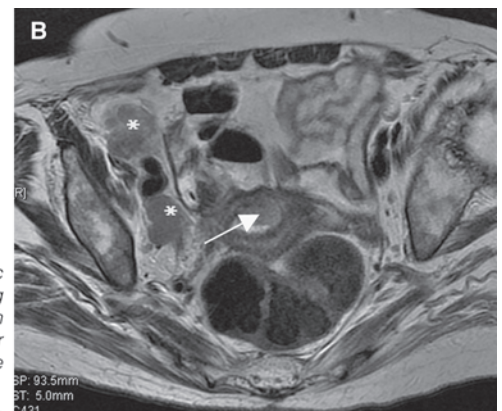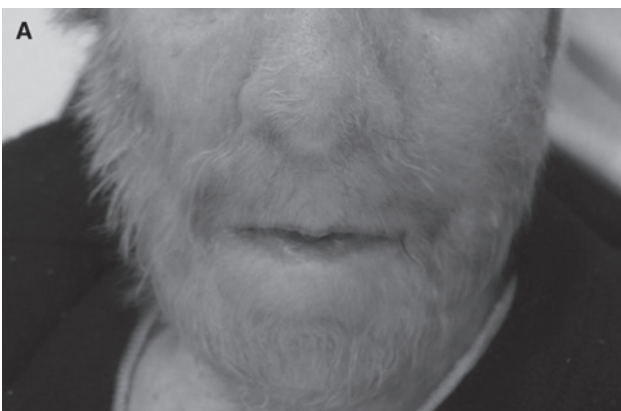
**Ramon M Pujol**, Dermatologist

Department of Dermatology and Department of Pathology, Hospital del Mar, Barcelona, Spain.

[mferran@imas.imim.es](mailto:mferran@imas.imim.es)

1 Chung VQ, Moschella SL, Zembowicz A, Liu V. Clinical and pathologic findings of paraneoplastic dermatoses. *J Am Acad Dermatol* 2006; 54: 745-762.

2 Sindhuphak W, Vibhagool A. Acquired hypertrichosis lanuginosa. *Int J Dermatol* 1982; 21: 599-601. □



**B:** Pelvic magnetic resonance imaging revealed an endometrial tumour (arrow) and multiple enlarged lymph nodes (asterisks).