

# Diagnosing, monitoring and managing behavioural variant frontotemporal dementia

Olivier Piguet<sup>1,2</sup>, Fiona Kumfor<sup>1,2</sup>, John Hodges<sup>1,3</sup>

**F**rontotemporal dementias (FTDs) are progressive neurodegenerative brain conditions characterised by brain atrophy in the prefrontal cortices or the anterior portions of the temporal lobes caused by various intraneuronal inclusions and abnormal protein depositions. FTD has a prevalence of 10–15/100 000 population in individuals aged 45–65 years, and is a common cause of younger onset dementia, although with large variability across studies.<sup>1,2</sup> Recent evidence indicates that the occurrence of FTD beyond 65 years of age appears to be more common than previously assumed.<sup>2</sup>

Unlike Alzheimer disease (AD), the clinical profile and pathology of FTD are heterogeneous and characterised by two main phenotypes: a progressive deterioration in behaviour and personality, known as behavioural variant FTD (bvFTD); and a decline in language skills, known as primary progressive aphasia, which is further subdivided according to the main pattern of language breakdown into progressive non-fluent aphasia and semantic dementia.<sup>3,4</sup> This review focuses on bvFTD. Although bvFTD is recognised as a potential cause of both major and mild neurocognitive disorder in the fifth edition of the *Diagnostic and statistical manual of mental disorders*,<sup>5</sup> the international consensus criteria published in 2011<sup>3</sup> are usually preferred in the clinic.

Substantial clinical and pathological overlap exists between FTD and motor neuron disease (MND) as well as other extrapyramidal motor disorders. About 10% of patients with FTD have features of MND.<sup>6,7</sup> Similarly, about 40% of patients with MND will develop behavioural or language deficits. In some instances, these deficits are severe enough to meet the FTD diagnostic criteria.<sup>8</sup> FTD can also overlap with two other movement disorders — corticobasal degeneration and progressive supranuclear palsy — with which it shares abnormal tau pathology.<sup>9</sup>

## Clinical presentation

The clinical presentation of bvFTD is that of progressive changes in personality, interpersonal conduct and emotion processing, which reflect the pathological changes in the brain networks supporting social cognition, emotion regulation, motivation and decision making (Box 1). This presentation contrasts with that of AD, where patients and their carers tend to report cognitive deficits, most commonly regarding episodic memory, while social graces remain relatively intact. As insight is commonly affected, it is crucial to interview a family member or a close friend to document the nature, severity, and progression of these early signs and symptoms. Additional information can be gathered from questionnaires aimed at carers.<sup>10–12</sup> These questionnaires systematically probe for the presence and severity of various symptoms found in different types of dementia and are therefore helpful with differential diagnosis.<sup>10–12</sup> What differentiates bvFTD from other dementias is not so much the presence of particular features, which are also found in other dementias, but rather their early presence and severity.

## Summary

- Behavioural variant frontotemporal dementia is characterised by insidious changes in personality and interpersonal conduct that reflect progressive disintegration of the neural circuits involved in social cognition, emotion regulation, motivation and decision making.
- The underlying pathology is heterogeneous and classified according to the presence of intraneuronal inclusions of tau, TDP-43 or, occasionally, fused in sarcoma proteins. Biomarkers to detect these histopathological changes in life are increasingly important with the development of disease-modifying drugs.
- A number of gene abnormalities have been identified, the most common being an expansion in the *C9orf72* gene, which together account for most familial cases.
- The 2011 international consensus criteria propose three levels of diagnostic certainty: possible, probable and definite. Detailed history taking from family members to elicit behavioural features underpins the diagnostic process, with support from neuropsychological testing designed to detect impairment in decision making, emotion processing and social cognition. Brain imaging is important for increasing the level of diagnosis certainty over time. Carer education and support remain of paramount importance.

The presence of socially inappropriate behaviours (eg, disinhibition, socially inappropriate comments), stereotypical motor behaviour, and changes in eating habits (eg, increased food intake, hyperorality) are features that most clearly help distinguish bvFTD from AD in the early stages of the disease.<sup>13,14</sup> As the condition advances, agitation and general irritability (ie, shortness of temper) seem to become more frequent, generally mixed with periods of apathy,<sup>15,16</sup> while restlessness and hyperorality remain common throughout.<sup>17</sup> Importantly, psychiatric elements such as delusions, paranoid ideation and hallucinations are relatively rare in bvFTD, except in patients harbouring the hexanucleotide repeat expansion in the *C9orf72* gene, where psychosis has been documented in up to 40% of patients.<sup>18,19</sup>

Behavioural assessment is a crucial aspect of the examination when bvFTD is suspected. This investigation is sensitive and is a useful adjunct to the standard cognitive testing in helping to distinguish between bvFTD and AD. Although knowledge of the behavioural changes in bvFTD has increased markedly in recent years, the neural basis of these changes and their relation to underlying pathology remain poorly understood.

## Cognitive profile of patients with bvFTD

In the early stages, patients with bvFTD may perform relatively well on formal tests of cognition, despite their personality and behavioural changes. The Mini-Mental State Examination is insensitive, but general screening measures that assess the major

## 1 Symptoms characteristic of behavioural variant frontotemporal dementia

Symptom	Clinical characteristics
Apathy	Very common; manifests as inertia, reduced motivation, lack of interest in previous hobbies, and progressive social isolation
Disinhibition	Often coexists with apathy; produces impulsive actions leading to overspending, tactless or sexually inappropriate remarks, and a range of socially embarrassing behaviours
Repetitive or stereotypic behaviour	May be apparent with perseveration and a tendency to repeat phrases, stories or jokes
Hoarding	When severe can result in squalor
Mental rigidity	Common; patients may have difficulty adapting to new situations or routines
Blunting of affect	Frequent reduction in range of emotional expression; elevation of mood resembling hypomania may also be seen
Changes in eating behaviour	Impaired satiety; change in preferences towards sweet food; common dysregulation of food intake
Loss of empathy	Common early symptom; lack of empathy towards others; inappropriate or subdued grief reaction
Other symptoms	New onset pathological gambling; hyper-religiosity (rare)

Reproduced with permission from Piguet O, Hodges JR. Behavioural-variant frontotemporal dementia: an update. *Dement Neuropsychol* 2013; 7: 10-18. ♦

domains of cognition, such as the Addenbrooke's Cognitive Examination<sup>20</sup> offer improved detection.<sup>21</sup> Performance on tasks assessing executive function may be variable despite being a central diagnostic feature.<sup>4</sup> This variability may, in part, reflect the breadth of executive functions (eg, planning versus inhibition versus reasoning), and associated divergent neuroanatomical correlates. Tasks assessing disinhibition (eg, Hayling test) or generativity (eg, verbal fluency) appear particularly sensitive to bvFTD,<sup>22</sup> and recent attempts to develop short executive function batteries have also shown promising results.<sup>23,24</sup> Experimental tasks adopted from neuroeconomic theory, which focuses on behaviours such as social decision making, small short term gain versus larger long term gain, and aversion to monetary loss, have also shown promise. These tasks, which directly tap decision-making capacity, have helped further characterise the cognitive deficits seen in this syndrome.<sup>25,26</sup>

Relative sparing of episodic memory has long been considered a defining feature, and is recognised in the current diagnostic criteria;<sup>4</sup> however, episodic memory capacity is variable, with some patients showing a similar amnesic profile to that seen in AD.<sup>27</sup> Indeed, a small proportion (10–15%) of patients with bvFTD present with severe memory deficits, which affect all aspects of episodic memory such as novel information learning, personal (autobiographical) memory, and tests of future thinking.<sup>28</sup> Nevertheless, assessment of topographical memory (eg, supermarket orientation task) shows promise in differentiating bvFTD from AD.<sup>29</sup> Box 2 summarises the main features of bvFTD and AD with regard to the levels of clinical diagnostic certainty.

Disturbance of emotion processing and emotion regulation is another diagnostic criterion for the disease (ie, early emotional blunting, early decline in social interpersonal conduct).<sup>4</sup> This clinical profile, together with recognition of overlap between the pattern of

atrophy in bvFTD and the “social brain”<sup>30</sup> has led to a rapid emergence of research on social cognition, including emotion recognition, theory of mind and empathy, in bvFTD over the past decade.

In contrast to patients with AD, those with bvFTD show widespread early deficits in social cognition. Early research has found a striking facial emotion recognition deficit early on.<sup>31</sup> Difficulties in recognising emotions are observed across a range of modalities (eg, photos, films, voices) and extend to complex emotions, such as embarrassment.<sup>32</sup> The extent that a decline in face processing capacity may compound emotion recognition impairments has recently been explored, with some evidence that face and emotion processing interact.<sup>33</sup> Performance on some emotion recognition tasks appears to be compounded in part by the presence of additional cognitive deficits.<sup>34</sup> These cognitive deficits may be amenable to retraining, which would potentially improve emotion processing as well as have a positive impact on interpersonal interactions.

Complex social cognition is also reduced in bvFTD, affecting varied skills such as theory of mind (ie, ability to infer intention and mental states in others), detection of social faux pas, discrimination of sincere from sarcastic exchanges, and moral judgement.<sup>35</sup> The loss of empathy and coldness commonly reported by carers<sup>36</sup> has further been demonstrated on objective measures, such as the Empathy for Pain task<sup>37</sup> and the Multifaceted Empathy Task.<sup>38</sup>

Recently, deficits of social cognition have been interpreted as an inability to process and integrate relevant contextual information.<sup>39</sup> This was in part driven by the observation that despite carers reporting profound changes in behaviour and social recognition, evidence of these behaviours can be difficult to elicit in the clinic. This apparent contradiction seems to reflect the fact that clinicians often become the patient's “frontal lobes” during testing (eg, providing a focused, distraction-free environment). Hence, tests that incorporate contextual information and reflect ecological situations will be important for future research to examine. Clinically suitable tests of emotion and sarcasm detection exist,<sup>40,41</sup> which also track disease progression.<sup>42</sup> Thus, integration of social cognition tests is essential to complement the typical cognitive assessment in individuals where a differential diagnosis of bvFTD is considered.

## Structural and functional neuroimaging

Early bilateral anterior brain atrophy (orbitofrontal, anterior cingulate, frontal insula) is observed on neuroimaging in bvFTD.<sup>43</sup> Changes are not limited to the grey matter and the cortical surface, with additional involvement of the frontal white matter tracts, in particular those connecting subregions within the frontal lobe (eg, genu of the corpus callosum) or those connecting frontal and temporal brain regions (eg, uncinate fasciculus).<sup>44</sup>

The region comprising the anterior cingulate and frontal insula cortices contains von Economo cells. This unique population of neurons, which is involved in the development and maintenance of social cognition, is severely reduced in patients with bvFTD at autopsy.<sup>45</sup> Patients with bvFTD experience additional changes in structural and functional connectivity in these regions sensitive to early atrophy, and more so than patients with other forms of dementia (Box 3, A).<sup>46,47</sup> Although the location and severity of grey matter atrophy has been suggested to be predictive of the underlying pathology in bvFTD, the location and severity of the brain atrophy appear to relate more closely to clinical features than to specific pathologies.<sup>48</sup>

## 2 Diagnostic classification of behavioural variant frontotemporal dementia and Alzheimer disease

Behavioural variant frontotemporal dementia*	Alzheimer disease <sup>†</sup>
<b>Core clinical description</b>	
Progressive deterioration of behaviour and/or cognition by observation or history	Progressive decline in functional ability with cognitive and/or behavioural changes involving at least two of the following domains: episodic memory, reasoning skills, visuospatial skills, language, personality and behaviour
<b>Possible</b>	
Three of the following behavioural/cognitive symptoms must be present; symptoms must be persistent or recurrent: <ul style="list-style-type: none"> <li>• early behavioural disinhibition</li> <li>• early apathy or inertia</li> <li>• early loss of sympathy or empathy</li> <li>• early perseverative, stereotyped or compulsive behaviour</li> <li>• hyperorality and dietary changes</li> <li>• neuropsychological profile of executive deficits with relative sparing of memory and visuospatial function</li> </ul>	Atypical course that meets the clinical/cognitive profile of probable AD (see below) but with sudden onset or lacking history of progression Mixed presentation of clinical symptoms but with the presence of concomitant cerebrovascular disease, non-neurological medical comorbidity, or features of dementia with Lewy bodies
<b>Probable</b>	
Must meet all the following criteria: <ul style="list-style-type: none"> <li>• meets criteria for possible bvFTD</li> <li>• exhibits significant functional decline</li> <li>• brain imaging results show either reduced structural (atrophy on CT or MRI) or functional (hypoperfusion or hypometabolism) integrity in the frontal and/or anterior temporal brain regions</li> </ul>	Meets criteria for dementia with additional features: <ul style="list-style-type: none"> <li>• insidious onset over months to years</li> <li>• clear history of worsening cognition</li> <li>• most prominent cognitive deficits on examination are in one of the following categories: amnesic (most common) or non-amnesic (language, executive or visuospatial) presentations</li> </ul>
<b>Definite</b>	
Meets the criteria for either possible or probable bvFTD and either one of the following: <ul style="list-style-type: none"> <li>• histopathological evidence of frontotemporal lobar degeneration on biopsy or at autopsy</li> <li>• presence of a known pathogenic mutation</li> </ul>	<b>Probable or possible with evidence of pathophysiology<sup>‡</sup></b> Meets criteria for probable AD with either of the following: <ul style="list-style-type: none"> <li>• positive presence of amyloid-<math>\beta</math> biomarkers on either brain imaging (elevated uptake on PIB-PET imaging) or CSF measurement (low amyloid-<math>\beta</math>-42 levels)</li> <li>• presence of either elevated CSF tau levels (either total or phospho), decreased FDG uptake on PET in the temporoparietal cortex, or disproportionate atrophy in the medial temporal lobe region on structural MRI</li> </ul>

AD = Alzheimer disease; bvFTD = behavioural variant frontotemporal dementia; CSF = cerebrospinal fluid; CT = computed tomography; FDG = fluorodeoxyglucose; MRI = magnetic resonance imaging; PET = positron emission tomography; PIB = Pittsburgh compound B. \* Rascovsky K et al.<sup>3</sup> † McKhann GM, Knopman DS, Chertkow H, et al. The diagnosis of dementia due to Alzheimer's disease: recommendations from the National Institute of Aging-Alzheimer's Association workgroups on diagnostic guidelines for Alzheimer's disease. *Alzheimer Dement* 2011; 7: 263-269. ‡ This category is currently intended for research purposes. ◆

Reduction in functional and structural connectivity in subcortical structures (eg, amygdala, striatum, thalamus) have also been documented.<sup>49,50</sup> Over time, grey and white matter changes become increasingly widespread and include posterior brain regions.<sup>51,52</sup> This pattern is in contrast to the progression of atrophy in AD, which tends to follow a reverse posterior-to-anterior gradient (Box 3, B and C).<sup>47</sup>

Differential patterns of brain atrophy have been found in the genetic forms of bvFTD, with a more bilateral anterior temporal profile in patients carrying a *MAPT* mutation, compared with an increased parietal involvement in patients carrying a *GRN* mutation. Studies of patients with the *C9orf72* expansion suggest a mild cortical atrophy with cerebellar involvement,<sup>53</sup> with some patients exhibiting very little, if any, atrophy at first presentation.<sup>54</sup> Recent investigations of asymptomatic carriers of genetic abnormalities have demonstrated that changes in structural brain integrity may be present up to 15 years before the onset of clinical signs.<sup>55</sup>

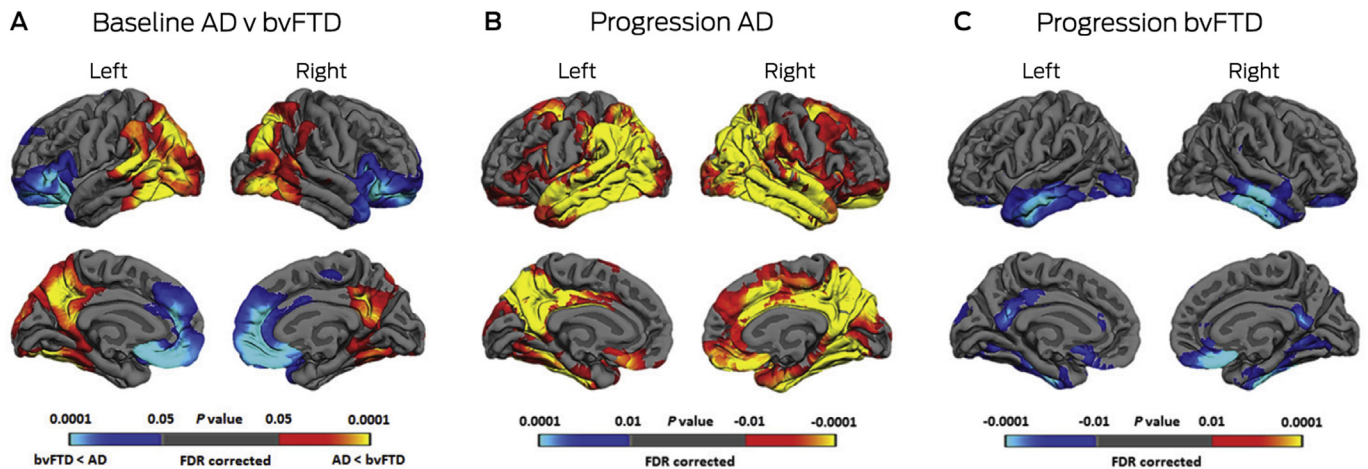
In most cases, atrophy in the frontal regions (medial, orbitofrontal and anterior insula) can easily be observed visually on magnetic resonance imaging (MRI) acquired in the coronal plane. Importantly, however, a seemingly normal MRI on visual inspection does not entirely rule out a diagnosis of bvFTD, as early changes may be subtle.

Functional neuroimaging is a helpful adjunct to diagnosis. Frontal hypoperfusion on hexamethylpropyleneamine oxime

single-photon emission computed tomography is commonly seen in bvFTD. This pattern of hypoperfusion contrasts with that found in AD, which predominantly involves the temporoparietal and posterior cingulate brain regions.<sup>56</sup> A consistent and reliable similar anterior–posterior contrasting profile of hypometabolism is found on fluorodeoxyglucose positron emission tomography (PET) between bvFTD (frontal) and AD (posterior) early in the disease process.<sup>57</sup> This metabolic reduction on fluorodeoxyglucose PET is detected before any abnormalities are visible on structural MRI images, making it the most sensitive diagnostic tool currently available. Because focal frontal atrophy is a positive marker of FTD, little additional diagnostic benefit may be gained by conducting a PET scan in patients with clear brain atrophy on structural MRI.

In recent years, several  $\beta$ -amyloid-detecting PET tracers have been developed. These show promising results in discriminating between cases with and without underlying AD pathology (eg, [<sup>11</sup>C]-Pittsburgh compound B, florbetapir, florbetaben),<sup>58</sup> particularly in patients presenting with aphasia rather than behavioural changes. Its use as a routine test remains to be established, as about 30% of cognitively intact individuals over the age of 70 years will return a positive scan. Some radiotracers targeting tau protein aggregations are available (eg, THK5351, AV1451) but currently lack the specificity required for broad clinical applicability.<sup>59</sup> No radiotracer targeting transactive response DNA-binding protein 43 kDa (TDP-43) is currently available. In summary, neuroimaging investigations are useful diagnostic tests that can help differentiate

### 3 Patterns of brain atrophy in behavioural variant frontotemporal dementia and Alzheimer disease and progression over time



AD = Alzheimer's disease. bvFTD = behavioural variant frontotemporal dementia. FDR = false discovery rate. **A:** Differences in the patterns of cortical thinning at baseline in bvFTD (blue) and AD (yellow-red). **B:** Annual progression in AD. **C:** Annual progression in bvFTD. Reproduced with permission from Landin-Romero et al.<sup>47</sup> ◆

bvFTD from other FTD subtypes and from other dementia syndromes.

#### FTD pathology

The neuropathologies of FTD are classified according to the distribution of protein accumulation in the brain, referred to as frontotemporal lobar degeneration (FTLD).<sup>60</sup> In FTD, the brain exhibits frontotemporal atrophy in both hemispheres with neuronal loss, microvacuolation and variable astrocytic gliosis, as well as different types of protein accumulations.<sup>61</sup>

The abnormal intracellular accumulation of the hyperphosphorylated protein tau is found in about 40% of FTD cases (FTLD-tau). Tau is involved in cell stability and plays a central role in neuronal integrity. Tau-positive cases are further classified based on the types of inclusions, with either three or four microtubule-binding repeat tau inclusions. Most other cases are tau-negative and ubiquitin-positive, with inclusions comprising TDP-43 (FTLD-TDP). TDP-43 is involved in multiple aspects of RNA processing. About 5–10% of cases are tau- and TDP-43-negative and show fused in sarcoma (FUS) protein inclusions (FTLD-FUS). Finally, a small proportion of cases have either no inclusions or show ubiquitin inclusions which are TDP-43- and FUS-negative, suggesting that other protein abnormalities exist in FTLD. In bvFTD, all neuropathological types are found; FTLD-tau and FTLD-TDP are detected in equal proportions,<sup>62</sup> and there are a small number of FTLD-FUS cases.<sup>63</sup> Currently, there are no reliable methods that enable the detection of pathology in life. With the development disease-modifying therapies, however, accurate determination of pathology in vivo is becoming increasingly important.

#### FTD genetics

Up to 40% of patients with FTD have a positive family history of dementia<sup>64</sup> with an autosomal dominant pattern of inheritance found in 10–20% of cases.<sup>65</sup> Mutations on two genes found on chromosome 17 (*MAPT* and *GRN*) account for 5–12% of total FTD cases each.<sup>66</sup> In 2011, a hexamino acid expansion on the *C9orf72* gene was identified,<sup>67,68</sup> which is now the most common gene abnormality in patients with FTD.<sup>69</sup> This abnormality is very commonly associated with families presenting with a

combination of either FTD, MND or a combination of both, as well as some apparently sporadic cases.<sup>20</sup> Mutations in the *VCP*, *CHMP2B*, and *TBK1* genes have been found to cause FTD, but these are rare.<sup>70</sup>

From a clinical viewpoint, a detailed family history is recommended whenever FTD or MND is suspected, given the overlap between these two disorders. Clinical variability within families with the same gene mutation should also be considered. Indeed, one family member may present with bvFTD while others may have a progressive aphasia phenotype or a corticobasal syndrome. Screening for the presence of abnormality in the *MAPT*, *GRN* and *C9orf72* genes is recommended in all patients with one or more first-degree relatives with a disease within the FTD spectrum, including MND. In the context of a combined presentation of FTD with MND, a family history of MND or features of psychosis, screening for *C9orf72* mutation should be conducted first. Involvement of a clinician trained in genetic counselling or referral to an appropriate clinical genetics service is paramount.

#### Management of patients

There are currently no interventions or drugs that are specific for FTD. As such, treatment is mostly symptomatic, combining pharmacological and non-pharmacological measures, aimed at reducing the impact of debilitating symptoms.<sup>71</sup> Evidence in support of pharmacological interventions in FTD is mixed. To date, only small treatment trials have been conducted, many of which have not considered the impact of the intervention on carer stress as a main outcome. These include trials of selective serotonin reuptake inhibitors to treat disinhibition and challenging behaviours,<sup>72,73</sup> or atypical antipsychotics (eg, olanzapine) for agitation, aggressive behaviour or psychosis.<sup>74</sup> Acetylcholinesterase inhibitors, commonly used in AD, do not show benefits in the treatment of FTD.<sup>75,76</sup> Similarly, trials of memantine, a non-competitive inhibitor of N-methyl-D-aspartate receptors, have not shown any significant symptom improvement but a worsening in cognition.<sup>77</sup> Recently completed double-blind, placebo-controlled trials of leuco-methylthionium bis(hydromethanesulfonate), a drug targeting tau protein aggregation, failed to show any benefits in bvFTD or in AD.<sup>78</sup>

In the absence of disease-modifying medications, non-pharmacological interventions remain the most appropriate action. Because of their reduced insight, difficult behaviours in bvFTD patients are best addressed using redirection or distractions and a predictable environment. Nevertheless, applications of novel technologies such as virtual reality to manage behaviour appear promising.<sup>79</sup> In the later stages of the disease, direct interventions that target a particular symptom (eg, repetitive behaviour) have had positive outcomes.<sup>80</sup> Although such interventions are highly individualised, they can be applied to any condition in which such symptoms are present.

Overall, the burden is much greater for carers looking after patients with FTD compared with other dementias,<sup>81</sup> predominantly due to the behavioural changes present in bvFTD.<sup>82</sup> In addition, a younger age at disease onset and increased disease severity also appear to contribute to the severity of burden in carers.<sup>83</sup> Direct carer interventions (eg, carer support groups, behaviour management techniques and education about the disease) are promising avenues with evidence of success in reducing distress and improving coping strategies,<sup>84</sup> as well as in understanding the disease.<sup>80</sup> Importantly, aspects of carer health (eg, depression, psychological wellbeing) also contribute to carer stress.<sup>81</sup>

## Final remarks and recommendations

Our understanding of the phenomenology and pathology of bvFTD has improved considerably in the past 10–15 years. Prognosis, however, remains difficult and while the disease course is on average 5 years from the time of diagnosis, it is highly variable.<sup>85</sup> The major challenge is now to improve the prediction of bvFTD neuropathology during life, which will also help to predict disease progression and duration. Research into

disease biomarkers for the disease (eg, blood, cerebrospinal fluid) is promising but in its early days. Such research will become increasingly pertinent as novel pharmacological interventions are developed.

From a clinical viewpoint, clinicians (general practitioners, neurologists, psychiatrists) are encouraged to consider bvFTD as a possible diagnosis in the presence of progressive behavioural changes in midlife, particularly when combined with changes in eating habits or language disturbance. The combination of a detailed medical history, carer information, targeted neuropsychological testing (including investigations of social cognition) and brain neuroimaging will help to differentiate bvFTD from other dementia syndromes, or from psychiatric disorders (eg, major depressive disorder or bipolar disorder). Given the progressive nature of bvFTD, GPs have an important role to play throughout the disease course, as new symptoms emerge and others dissipate over time.<sup>42,86</sup> We also recommend referral to dementia clinics that specialise in younger onset dementia, and support programs and services for patients with younger onset dementia. Organisations such as the Australian Frontotemporal Dementia Association and Dementia Australia, and international bodies such as the Association for Frontotemporal Degeneration in the United States and Dementia UK, provide valuable support for patients and carers.

**Acknowledgements:** Olivier Piguet is supported by a National Health and Medical Research Council (NHMRC) Senior Research Fellowship (APP1103258). Fiona Kumfor is supported by an NHMRC–Australian Research Council Dementia Research Development Fellowship (APP1097026).

**Competing interests:** No relevant disclosures.

**Provenance:** Not commissioned; externally peer reviewed. ■

© 2017 AMPCo Pty Ltd. Produced with Elsevier B.V. All rights reserved.

- Ratnavalli E, Brayne C, Dawson K, et al. The prevalence of frontotemporal dementia. *Neurology* 2002; 58: 1615–1621.
- Coyle-Gilchrist IT, Dick KM, Patterson K, et al. Prevalence, characteristics, and survival of frontotemporal lobar degeneration syndromes. *Neurology* 2016; 86: 1736–1743.
- Rascovsky K, Hodges JR, Knopman D, et al. Sensitivity of revised diagnostic criteria for the behavioural variant of frontotemporal dementia. *Brain* 2011; 134: 2456–2477.
- Gorno-Tempini ML, Hillis AE, Weintraub S, et al. Classification of primary progressive aphasia and its variants. *Neurology* 2011; 76: 1006–1014.
- American Psychiatric Association. Diagnostic and statistical manual of mental disorders. 5th ed. Washington, DC: APA, 2013.
- Lillo P, Garcin B, Hornberger M, et al. Neurobehavioral features in frontotemporal dementia with amyotrophic lateral sclerosis. *Arch Neurol* 2010; 67: 826–830.
- Lomen-Hoerth C, Anderson T, Miller B. The overlap of amyotrophic lateral sclerosis and frontotemporal dementia. *Neurology* 2002; 59: 1077–1079.
- Lillo P, Mioshi E, Zoing MC, et al. How common are behavioural changes in amyotrophic lateral sclerosis? *Amyotroph Lateral Scler* 2011; 12: 45–51.
- Kertesz A, McMonagle P, Blair M, et al. The evolution and pathology of frontotemporal dementia. *Brain* 2005; 128: 1996–2005.
- Cummings JL, Mega M, Gray K, et al. The Neuropsychiatric Inventory: comprehensive assessment of psychopathology in dementia. *Neurology* 1994; 44: 2308–2314.
- Wedderburn C, Wear H, Brown J, et al. The utility of the Cambridge Behavioural Inventory in neurodegenerative disease. *J Neurol Neurosurg Psychiatry* 2008; 79: 500–503.
- Kertesz A, Davidson W, Fox H. Frontal behavioral inventory: diagnostic criteria for frontal lobe dementia. *Can J Neurol Sci* 1997; 24: 29–36.
- Ahmed RM, Irish M, Kam J, et al. Quantifying the eating abnormalities in frontotemporal dementia. *JAMA Neurol* 2014; 71: 1540–1546.
- Liu W, Miller BL, Kramer JH, et al. Behavioral disorders in the frontal and temporal variants of frontotemporal dementia. *Neurology* 2004; 62: 742–748.
- Diehl-Schmid J, Pohl C, Pernecky R, et al. Behavioral disturbances in the course of frontotemporal dementia. *Dement Geriatr Cogn Disord* 2006; 22: 352–357.
- Srikanth S, Nagaraja AV, Ratnavalli E. Neuropsychiatric symptoms in dementia—frequency, relationship to dementia severity and comparison in Alzheimer's disease, vascular dementia and frontotemporal dementia. *J Neurol Sci* 2005; 236: 43–48.
- Pasquier F, Lebert F, Lavenu I, et al. The clinical picture of frontotemporal dementia: diagnosis and follow-up. *Dement Geriatr Cogn Disord* 1999; 10 Suppl 1: 10–14.
- Snowden JS, Rollinson S, Thompson JC, et al. Distinct clinical and pathological characteristics of frontotemporal dementia associated with C9ORF72 mutations. *Brain* 2012; 135: 693–708.
- Devenney E, Hornberger M, Irish M, et al. Frontotemporal dementia associated with the C9ORF72 mutation: a unique clinical profile. *JAMA Neurol* 2014; 71: 331–339.
- Hsieh S, Schubert S, Hoon C, et al. Validation of the Addenbrooke's Cognitive Examination III in frontotemporal dementia and Alzheimer's disease. *Dement Geriatr Cogn Disord* 2013; 36: 242–250.
- Kipps CM, Nestor PJ, Dawson CE, et al. Measuring progression in frontotemporal dementia: Implications for therapeutic interventions. *Neurology* 2008; 70: 2046–2052.
- Hornberger M, Savage S, Hsieh S, et al. Orbitofrontal dysfunction discriminates behavioral variant frontotemporal dementia from Alzheimer's disease. *Dement Geriatr Cogn Disord* 2010; 30: 547–552.
- Leslie F, Foxe D, Daveson N, et al. FRONTIER Executive Screen: a brief executive battery to differentiate frontotemporal dementia and Alzheimer's disease. *J Neurol Neurosurg Psychiatry* 2016; 87: 831–835.
- Torralva T, Roca M, Gleichgerricht E, et al. INECO Frontal Screening (IFS): a brief, sensitive, and specific tool to assess executive functions in dementia. *J Int Neuropsychol Soc* 2009; 15: 777–786.
- Chiong W, Wood KA, Beagle AJ, et al. Neuroeconomic dissociation of semantic dementia and behavioural variant frontotemporal dementia. *Brain* 2016; 139: 578–587.
- O'Callaghan C, Bertoux M, Irish M, et al. Fair play: social norm compliance failures in behavioural variant frontotemporal dementia. *Brain* 2016; 139: 204–216.
- Hornberger M, Piguet O. Episodic memory in frontotemporal dementia: a critical review. *Brain* 2012; 135: 678–692.
- Irish M, Hornberger M, Lah S, et al. Profiles of recent autobiographical memory retrieval in semantic dementia, behavioural-variant frontotemporal dementia, and Alzheimer's disease. *Neuropsychologia* 2011; 49: 2694–2702.
- Tu S, Wong S, Hodges JR, et al. Lost in spatial translation - a novel tool to objectively assess spatial disorientation in Alzheimer's disease and frontotemporal dementia. *Cortex* 2015; 67: 83–94.

- 30 Kennedy DP, Adolphs R. The social brain in psychiatric and neurological disorders. *Trends Cogn Sci* 2012; 16: 559-572.
- 31 Kumfor F, Piguet O. Disturbance of emotion processing in frontotemporal dementia: a synthesis of cognitive and neuroimaging findings. *Neuropsychol Rev* 2012; 22: 280-297.
- 32 Sturm VE, Sollberger M, Seeley WW, et al. Role of right pregenual anterior cingulate cortex in self-conscious emotional reactivity. *Soc Cogn Affect Neurosci* 2013; 8: 468-474.
- 33 Hutchings R, Palermo R, Piguet O, et al. Disrupted face processing in frontotemporal dementia: a review of the clinical and neuroanatomical evidence. *Neuropsychol Rev* 2017; 27: 18-30.
- 34 Miller LA, Hsieh S, Lah S, et al. One size does not fit all: face emotion processing impairments in semantic dementia, behavioural-variant frontotemporal dementia and Alzheimer's disease are mediated by distinct cognitive deficits. *Behav Neurol* 2012; 25: 53-60.
- 35 Bora E, Walterfang M, Velakoulis D. Theory of mind in behavioural-variant frontotemporal dementia and Alzheimer's disease: a meta-analysis. *J Neurol Neurosurg Psychiatry* 2015; 86: 714-719.
- 36 Fernandez-Duque D, Hodges SD, Baird JA, et al. Empathy in frontotemporal dementia and Alzheimer's disease. *J Clin Exp Neuropsychol* 2010; 32: 289-298.
- 37 Baez S, Manes F, Huepe D, et al. Primary empathy deficits in frontotemporal dementia. *Frontiers Aging Neurosci* 2014; 6: 262.
- 38 Oliver LD, Mitchell DG, Dziobek I, et al. Parsing cognitive and emotional empathy deficits for negative and positive stimuli in frontotemporal dementia. *Neuropsychologia* 2015; 67: 14-26.
- 39 Ibanez A, Manes F. Contextual social cognition and the behavioral variant of frontotemporal dementia. *Neurology* 2012; 78: 1354-1362.
- 40 McDonald S, Flanagan S, Rollins J, et al. TASIT: a new clinical tool for assessing social perception after traumatic brain injury. *J Head Trauma Rehabil* 2003; 18: 219-238.
- 41 Bertoux M, Volle E, Funkiewiez A, et al. Social Cognition and Emotional Assessment (SEA) is a marker of medial and orbital frontal functions: a voxel-based morphometry study in behavioral variant of frontotemporal degeneration. *J Int Neuropsychol Soc* 2012; 18: 972-985.
- 42 Kumfor F, Irish M, Leyton CE, et al. Tracking the progression of social cognition in neurodegenerative disorders. *J Neurol Neurosurg Psychiatry* 2014; 85: 1076-1083.
- 43 Boccardi M, Sabatoli F, Laakso MP, et al. Frontotemporal dementia as a neural system disease. *Neurobiol Aging* 2005; 26: 37-44.
- 44 Agosta F, Scola E, Canu E, et al. White matter damage in frontotemporal lobar degeneration spectrum. *Cereb Cortex* 2012; 22: 2705-2714.
- 45 Seeley WW. Selective functional, regional, and neuronal vulnerability in frontotemporal dementia. *Curr Opin Neurol* 2008; 21: 701-707.
- 46 Seeley WW, Crawford RK, Zhou J, et al. Neurodegenerative diseases target large-scale human brain networks. *Neuron* 2009; 62: 42-52.
- 47 Landin-Romero R, Kumfor F, Leyton CE, et al. Disease-specific patterns of cortical and subcortical degeneration in a longitudinal study of Alzheimer's disease and behavioural-variant frontotemporal dementia. *Neuroimage* 2017; 151: 72-80.
- 48 Pereira JM, Williams GB, Acosta-Cabrero J, et al. Atrophy patterns in histologic vs clinical groupings of frontotemporal lobar degeneration. *Neurology* 2009; 72: 1653-1660.
- 49 Gordon E, Rohrer JD, Fox NC. Advances in neuroimaging in frontotemporal dementia. *J Neurochem* 2016; 138: 193-210.
- 50 Filippi M, Agosta F, Scola E, et al. Functional network connectivity in the behavioral variant of frontotemporal dementia. *Cortex* 2013; 49: 2389-2401.
- 51 Lam BY, Halliday GM, Irish M, et al. Longitudinal white matter changes in frontotemporal dementia subtypes. *Hum Brain Map* 2014; 35: 3547-3557.
- 52 Whitwell JL, Boeve BF, Weigand SD, et al. Brain atrophy over time in genetic and sporadic frontotemporal dementia: a study of 198 serial magnetic resonance images. *Eur J Neurol* 2015; 22: 745-752.
- 53 Whitwell JL, Weigand SD, Boeve BF, et al. Neuroimaging signatures of frontotemporal dementia genetics: C9ORF72, tau, progranulin and sporadics. *Brain* 2012; 135: 794-806.
- 54 Devenney E, Bartley L, Hoon C, et al. Progression in behavioral variant frontotemporal dementia: a longitudinal study. *JAMA Neurol* 2015; 72: 1501-1509.
- 55 Rohrer JD, Nicholas JM, Cash DM, et al. Presymptomatic cognitive and neuroanatomical changes in genetic frontotemporal dementia in the Genetic Frontotemporal Dementia Initiative (GENFI) study: a cross-sectional analysis. *Lancet Neurol* 2015; 14: 253-262.
- 56 Varma AR, Adams W, Lloyd JJ, et al. Diagnostic patterns of regional atrophy on MRI and regional cerebral blood flow change on SPECT in young onset patients with Alzheimer's disease, frontotemporal dementia and vascular dementia. *Acta Neurol Scand* 2002; 105: 261-269.
- 57 Kanda T, Ishii K, Uemura T, et al. Comparison of grey matter and metabolic reductions in frontotemporal dementia using FDG-PET and voxel-based morphometric MR studies. *Eur J Nucl Med Mol Imaging* 2008; 35: 2227-2234.
- 58 Morris E, Chalkidou A, Hammers A, et al. Diagnostic accuracy of <sup>18</sup>F amyloid PET tracers for the diagnosis of Alzheimer's disease: a systematic review and meta-analysis. *Eur J Nucl Med Mol Imaging* 2016; 43: 374-385.
- 59 Villemagne VL, Fodero-Tavoletti MT, Masters CL, et al. Tau imaging: early progress and future directions. *Lancet Neurol* 2015; 14: 114-124.
- 60 Cairns NJ, Bigio EH, Mackenzie IR, et al. Neuropathologic diagnostic and nosologic criteria for frontotemporal lobar degeneration: consensus of the Consortium for Frontotemporal Lobar Degeneration. *Acta Neuropathol (Berl)* 2007; 114: 5-22.
- 61 Mackenzie IR, Neumann M. Molecular neuropathology of frontotemporal dementia: insights into disease mechanisms from postmortem studies. *J Neurochem* 2016; 138 Suppl 1: 54-70.
- 62 Shi J, Shaw CL, Du Plessis D, et al. Histopathological changes underlying frontotemporal lobar degeneration with clinicopathological correlation. *Acta Neuropathol* 2005; 110: 501-512.
- 63 Seelaar H, Klijnsma KY, de Koning I, et al. Frequency of ubiquitin and FUS-positive, TDP-43-negative frontotemporal lobar degeneration. *J Neurol* 2010; 257: 747-753.
- 64 Wood EM, Falcone D, Suh E, et al. Development and validation of pedigree classification criteria for frontotemporal lobar degeneration. *JAMA Neurol* 2013; 70: 1411-1417.
- 65 Po K, Leslie FV, Gracia N, et al. Heritability in frontotemporal dementia: more missing pieces? *J Neurol* 2014; 261: 2170-2177.
- 66 Rohrer JD, Guerreiro R, Vandrovca J, et al. The heritability and genetics of frontotemporal lobar degeneration. *Neurology* 2009; 73: 1451-1456.
- 67 DeJesus-Hernandez M, Mackenzie IR, Boeve BF, et al. Expanded GGGGCC hexanucleotide repeat in noncoding region of C9ORF72 causes chromosome 9p-linked FTD and ALS. *Neuron* 2011; 72: 245-256.
- 68 Renton AE, Majounie E, Waite A, et al. A hexanucleotide repeat expansion in C9ORF72 is the cause of chromosome 9p21-linked ALS-FTD. *Neuron* 2011; 72: 257-268.
- 69 Hodges J. Familial frontotemporal dementia and amyotrophic lateral sclerosis associated with the C9ORF72 hexanucleotide repeat. *Brain* 2012; 135: 652-655.
- 70 Pottier C, Ravenscroft TA, Sanchez-Contreras M, et al. Genetics of FTL: overview and what else we can expect from genetic studies. *J Neurochem* 2016; 138 Suppl 1: 32-53.
- 71 Boxer AL, Boeve BF. Frontotemporal dementia treatment: current symptomatic therapies and implications of recent genetic, biochemical, and neuroimaging studies. *Alzheimer Dis Assoc Disord* 2007; 21: S79-S87.
- 72 Moretti R, Torre P, Antonello RM, et al. Frontotemporal dementia: paroxetine as a possible treatment of behavior symptoms. A randomized, controlled, open 14-month study. *Eur Neurol* 2003; 49: 13-19.
- 73 Deakin JB, Rahmsdorf S, Nestor PJ, et al. Paroxetine does not improve symptoms and impairs cognition in frontotemporal dementia: a double-blind randomized controlled trial. *Psychopharmacology (Berl)* 2004; 172: 400-408.
- 74 Moretti R, Torre P, Antonello RM, et al. Olanzapine as a treatment of neuropsychiatric disorders of Alzheimer's disease and other dementias: a 24-month follow-up of 68 patients. *Am J Alzheimers Dis Other Dement* 2003; 18: 205-214.
- 75 Moretti R, Torre P, Antonello RM, et al. Rivastigmine in frontotemporal dementia: an open-label study. *Drugs Aging* 2004; 21: 931-937.
- 76 Mendez MF, Shapira JS, McMurtry A, et al. Preliminary findings: behavioral worsening on donepezil in patients with frontotemporal dementia. *Am J Geriatr Psychiatry* 2007; 15: 84-87.
- 77 Boxer AL, Knopman DS, Kaufer DI, et al. Memantine in patients with frontotemporal lobar degeneration: a multicentre, randomised, double-blind, placebo-controlled trial. *Lancet Neurol* 2013; 12: 149-156.
- 78 Gauthier S, Feldman HH, Schneider LS, et al. Efficacy and safety of tau-aggregation inhibitor therapy in patients with mild or moderate Alzheimer's disease: a randomised, controlled, double-blind, parallel-arm, phase 3 trial. *Lancet* 2016; 388: 2873-2884.
- 79 Mendez MF, Joshi A, Jimenez E. Virtual reality for the assessment of frontotemporal dementia, a feasibility study. *Disabil Rehabil Assist Technol* 2015; 10: 160-164.
- 80 O'Connor CM, Clemson L, Brodaty H, et al. Enhancing caregivers' understanding of dementia and tailoring activities in frontotemporal dementia: two case studies. *Disabil Rehabil* 2016; 38: 704-714.
- 81 Mioshi E, Bristow M, Cook R, et al. Factors underlying caregiver stress in frontotemporal dementia and Alzheimer's disease. *Dement Geriatr Cogn Disord* 2009; 27: 76-81.
- 82 Boutoleau-Bretonniere C, Vercelletto M, Volteau C, et al. Zarit burden inventory and activities of daily living in the behavioral variant of frontotemporal dementia. *Dement Geriatr Cogn Disord* 2008; 25: 272-277.
- 83 Miller LA, Mioshi E, Savage S, et al. Identifying cognitive and demographic variables that contribute to carer burden in dementia. *Dement Geriatr Cogn Disord* 2013; 36: 43-49.
- 84 Mioshi E, McKinnon C, Savage S, et al. Improving burden and coping skills in frontotemporal dementia caregivers: a pilot study. *Alzheimer Dis Assoc Disord* 2013; 27: 84-86.
- 85 Garcin B, Lilo P, Hornberger M, et al. Determinants of survival in behavioral variant frontotemporal dementia. *Neurology* 2009; 73: 1656-1661.
- 86 Chow TW, Fridhandler JD, Binns MA, et al. Trajectories of behavioural disturbance in dementia. *J Alzheimers Dis* 2012; 31: 143-149. ■